

CLINICO-PATHOLOGICAL STUDY OF BREAST LESIONS AT A TERTIARY CARE TEACHING INSTITUTE

Durgeshwari Pandey¹, Neeraj Kumar Singh², Usha³, Vaishali D. Kotasthane⁴

¹Post Graduate, Heritage Institute of Medical Sciences, Varanasi, Uttar Pradesh, India

²Associate Professor, Heritage Institute of Medical Sciences, Varanasi, Uttar Pradesh, India

³Professor, Heritage Institute of Medical Sciences, Varanasi, Uttar Pradesh, India

⁴Professor & HOD, Heritage Institute of Medical Sciences, Varanasi, Uttar Pradesh, India

Received : 14/07/2023

Received in revised form : 25/08/2023

Accepted : 07/09/2023

Keywords:

Breast lesions, Clinicopathological, FNAC, Histopathological, IHC.

Corresponding Author:

Dr. Neeraj Kumar Singh,

Email: neerajpathology@gmail.com

DOI: 10.47009/jamp.2023.5.5.94

Source of Support: Nil,

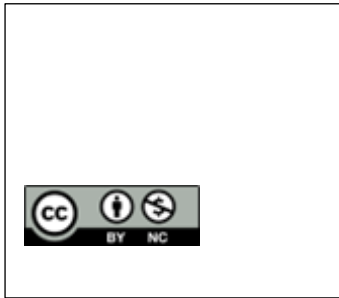
Conflict of Interest: None declared

Int J Acad Med Pharm

2023; 5 (5); 479-485

Abstract

Breast diseases are very common in medical practice. Breast is a target of many benign and malignant diseases, including cancer. Approximately 200000 cases of breast lesions were diagnosed annually. Benign breast disease are more prevalent as compared to malignant and inflammatory, Breast pathology encompasses a wide range of benign, atypical, and malignant lesions. The spectrum of benign breast lesion commonly included fibroadenoma, phyllodes tumor, breast abscess, and chronic mastitis and the malignant spectrum mostly included ductal carcinoma, lobular carcinoma, and medullary carcinoma. There are various methods to diagnose different breast diseases eg. FNAC, histopathology, ultrasonography supported by molecular techniques. Out of these techniques FNAC has become the most common method in evaluation of breast lesion. It is fast, reliable, safe, cost effective, minimal invasive technique with very low incidence of complications. Sensitivity and specificity of FNAC is 94% and 98% for diagnosis of malignant lesion and about 90% of accuracy rate of identification of malignancy. However histopathology is confirmatory test. Aim is to assess the clinical, cytological and histopathological features of breast lesion and objectives is to Study & classify various breast lesions according to WHO 2019 criteria, To correlate the cytological finding with histopathological finding wherever available, To study the Immunohistochemistry finding of ER, PR, HER-2 in malignant lesion and its clinical correlation, To determine sensitivity, specificity and accuracy of FNAC in comparison to histopathology. were present upper outer quadrant (32%), 21% cases in upper inner quadrant, 23% cases in lower outer quadrant and 17% of cases were in lower inner quadrant is involved. Maximum number of cases were of benign breast lesion (77%) of cases followed by malignant breast lesions (15%). Successful material was obtained in 85 cases in FNAC, fibroadenoma was the most common lesions (52.94%) followed by fibrocystic disease (16.47%), benign proliferative disease is (10.58%), fat necrosis (3.52%), gynecomastia (8.23%), granulomatous pathology (2.35%) Total 100 cases were taken, maximum number of cases – 32% were in 3rd decade, 59% were in between 21-40 years, about 17% of the cases were seen in second decade. Youngest patient was 14 years old and eldest was 87 years old. Lesions decline after 50 years (13%). Gender wise analysis shows that majority of patients were female (93%) who had breast disease breast lesion were more common in left breast (46%) followed by right breast (41%) while in 13% cases both breast were involved. 48% patient presented between 4-6 months 33% patient came to doctor in <3 months and 18 % cases presented between 7-9 months. Only one patient presented after 9 months All patients presented as lump of breast, second most presentation was 32%, followed by discharge from breast (17%) weight loss and pain of breast was seen in 16% of cases. Maximum number of lesions of breast and in (1.17%) phyllodes was seen .Maximum number of cases were of invasive ductal carcinoma with 9(60%) cases, followed by atypia (20%), rest cases were of invasive papillary carcinoma, invasive lobular carcinoma and lymphoma (6.66% each cases). In 22 cases, histopathology was available for cyto-histo correlation, in histopathology also fibroadenoma was predominant



overall benign lesion, out of this 5 cases were of intracanalicular 3 cases of pericanalicular and 1 case had mixed picture and 1 had juvenile fibroadenoma. Case of complex fibroadenoma had composite picture and were seen in 27 Year old female. Lymph node was enlarged and involved only 14% of cases which showed tumor deposits. Out of 4 malignant cases we did IHC for 2 cases. One was ER/PR+ and HER2 – and other was ER/PR/HER2-NEU and both were Ki67 positive. Histopathology was superior than FNAC and was confirmatory test. Histopathology correlation was found in 70% cases. In 30% cases cytology did not correlate with histopathology. Sensitivity of FNAC was 75% but Specificity was 100%.

INTRODUCTION

Breast diseases are very common in medical practice. Breast is a target of many benign and malignant diseases, including cancer.^[1] Approximately 200,000 cases of breast lesions were diagnosed annually.^[2] Benign breast diseases are more prevalent as compared to malignant and inflammatory.^[3] Breast pathology encompasses a wide range of benign, atypical, and malignant lesions.^[4] Breast cancer is the most frequent cancer among women, impacting 2.1 million women each year, and also causes the greatest number of cancer-related deaths among women. In 2018, it is estimated that 627,000 women died from breast cancer—that is approximately 15% of all cancer deaths among women.^[5]

The spectrum of benign breast lesions commonly included fibroadenoma, phyllodes tumor, breast abscess, and chronic mastitis and the malignant spectrum mostly included ductal carcinoma, lobular carcinoma, and medullary carcinoma.^[6]

Breast cancer is the most common malignancy in developed nations in women. Clinical symptoms of breast diseases include breast lumps, breast pain or tenderness, nipple discharge or inversion and changes in skin of breast. These are common in women of all ages from adolescents to older women.^[6-10]

1 in 9 of those presenting with a breast lump will be diagnosed as breast cancer. Since it is not as yet preventable, its early detection gives the patient the best chance of a cure. The risk factors for breast cancer are numerous and can essentially be divided into hormonal, non-hormonal and genetic risk factors. Patients with a benign lump but having a family history of breast cancer also have an associated increased relative risk for cancer.^[11] There are various methods to diagnose different breast diseases e.g. FNAC, histopathology, ultrasonography supported by molecular techniques. Out of these techniques FNAC has become the most common method in evaluation of breast lesions. It is fast, reliable, safe, cost-effective, minimal invasive technique with very low incidence of complications. Sensitivity and specificity of FNAC is 94% and 98% for diagnosis of malignant lesions and about 90% of accuracy rate of identification of malignancy.^[12] However histopathology is confirmatory test.

Aim: To assess the clinical, cytological and histopathological features of breast lesions

Objectives

1. To study & classify various breast lesions according to WHO 2019 criteria
2. To correlate the cytological findings with histopathological findings wherever available
3. To study the immunohistochemistry findings of ER, PR, HER-2 in malignant lesions and its clinical correlation
4. To determine sensitivity, specificity and accuracy of FNAC in comparison to histopathology.

MATERIALS AND METHODS

The study was conducted at Heritage Institute of Medical Sciences, Varanasi following the due approval of Hospital Ethics and Scientific Committee after obtaining informed consent of patients to be included as subjects of study. It was an observational study. Patients of all age groups and both genders were included who had breast mass. Sample size: total 100 cases. Study duration: From January 2019–November 2020 (Retrospective study) and from December 2020–November 2022 (Prospective study). Sampling technique was Purposive technique.

H&E, Gimesa, PAP stains and IHC were done in the smears.

Inclusion Criteria

All patients presenting with breast lesions who are referred for breast FNAC or histopathology were included in the study. Patients of all age groups and both sexes were included.

Exclusion Criteria

Patient having known bleeding disorder. If patient is not willing to give consent

Statistical Method

The collected data were organized, tabulated. Statistical methods: Tables, Bar diagrams, Pie diagrams and Percentage used for descriptive purpose.

RESULTS

In the present study, total of 100 cytological smears of breast lesions were studied from March 2018 to September 2022. Histopathological correlation was present in 22% of cases.

- Total 100 cases were taken, maximum number of cases – 32% were in 3rd decade, 59% were between 21–40 years, about 17% of the cases were

seen in second decade. Youngest patient was 14 years old and eldest was 87 years old.

- Gender wise analysis shows that majority of patients were female (93%) who had breast disease.
- site wise distribution analysis reveals that breast lesion were more common in left breast (46%) followed by right breast (41%) while in 13% cases both breast were involved.
- 48% patient presented between 4-6 months, 33% patient came to doctor in <3 months and 18 % cases presented between 7-9 months. Only one patient presented after 9 months.
- All patients presented as lump of breast, second most presentation was tenderness (32%), followed by discharge from breast (17%), weight loss and pain of breast was seen in 16% of cases.
- Maximum number of lesions of breast were present in upper outer quadrant (32%), followed by upper inner quadrant (28%) cases, lower outer quadrant (23 %) cases and in 17% of cases lower inner quadrant was involved.

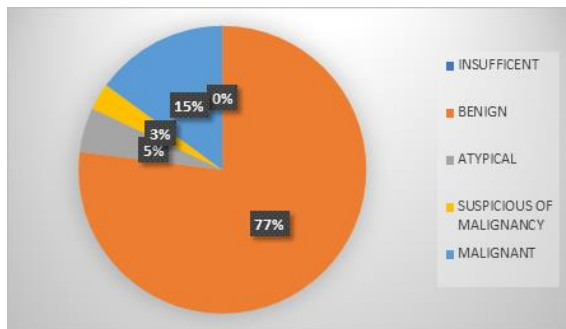


Figure 1: non-neoplastic and neoplastic lesions of breast on FNAC on basis of yokhama system (international acadamy of cytology)

Above picture demonstrate that maximum number of cases were of benign breast lesion (77% of cases) followed by malignant breast lesions (15% of cases). Atypical lesions were diagnosed in 5% cases and suspicious of malignancy in 3% cases.

Above table shows that in 85 cases (85% cases), breast lesions were benign. Fibroadenoma was the most common lesions (52.94%) followed by fibrocystic disease i.e (16.47%), benign proliferative disease (10.58%), gynecomastia (8.23%). Granulomatous mastitis (2.35%) and in one case (1.17%) phyllodes tumor was seen. Three cases were of fat necrosis(3.52%). [Table 2]

[Table 3] In 15 cases lesions were malignant, above table shows that maximum number of cases were of invasive ductal carcinoma with 9(60%) cases, followed by atypia (20%), rest (one case each) were of invasive papillary carcinoma, invasive lobular carcinoma and lymphoma with (6.66%).

In 22 cases HPE of breast was available. Like cytology in HPE also majority of lesions (63.63%) cases were benign only (18.18%) cases were diagnosed as malignant.

All inflammatory lesions and 64.28% benign lesions were found in women between 21-40 years. Contradictory to it malignant lesions were seen after 41-50 years and about 50 years.

In 22 cases, histopathology was available for cyto-histo correlation. In histopathology also fibroadenoma was predominant (55.5%) benign lesion, out of this 5, cases were of intracanalicular, 3 cases of pericanalicular and 1 cases had mixed picture and 1 had juvenile fibroadenoma. Granulomatous mastitis in 2 cases showed.

[Table 4] Only 4 cases in histopathology had malignant tumour.

One case had mixture of both invasive and lobular carcinoma this was seen in 57 year old lady, it involved right breast. Microscopically tumor cells infiltrating the stroma, predominantly in trabecular, Indian file and singly scattered pattern. This pattern comprises of >50% of tumor. Individual tumor cells are predominantly mildly pleomorphic with dispersed chromatin and scanty cytoplasm. Few cells show moderate pleomorphism with prominent nucleoli. Also seen are few solid nests and clusters of tumor cells comprising of <50%. intervening stroma showed dense lymphocytic infiltration and hyalinization.

Invasive / infiltrating duct carcinoma was seen in 2 cases, patient was 49 year and 55 year old one had lump in left side in upper outer quadrant and other also had lump in left side in upper inner quadrant.

One case of lymphoma was seen in 60 year old lady. It involved both breast. B/L breast tumors showed sheets of medium to large sized lymphoid cells with clumped nuclear chromatin and prominent nucleoli in lymphoid background, with areas of hemorrhages and abundant mitotic figures, lymphoma cell resembled non Hodgkin's lymphoma, however exact characterization was not possible because immunohistochemistry was not done.

[Table 5] In 22 cases both cytology and HPE was done, in 30% cases no correlation of cytology with HPE was found only 70% cases showed correlation. In fibroadenoma maximum correlation was found (6/7 cases) in granulomatous mastitis 1/3rd cases, malignancy (50%), fibrocystic disease of breast and benign proliferative breast diseases showed less correlation.

Two of the cases (1 case of IDC and 1 case of mixed carcinoma) were diagnosed as Fibrocystic disease and proliferative breast disease.

[Table 6] Statistical analysis suggest that although FNAC is a simple non traumatic procedure but its sensitivity is (75%) but it has high specificity (100%). Positive predictive value is 100% and accuracy of 95.45%.

[Table 7] Male breast lesion were seen in between 18 year to 87 years. In 41.7% cases left breast showed lesion in the form of lump whereas in only 3 cases, right breast lesion was found. Histopathologically all lesions were of Gynaecomastia.

Table 1: age wise distribution of lesions of breast in FNAC

Age group in years	Number of cases (100)	Percentage (%)
10-20	17	17%
21-30	32	32%
31-40	27	27%
41-50	11	11%
>50	13	13%

Table 2: Distribution of benign breast lesion in cytology

Cytological diagnosis	Number of cases (N=85)	Percentage (%)
Fibroadenoma	45	52.94
Phyllodes tumor	1	1.17%
Fibrocystic disease	14	16.47
Breast abscess	4	4.70%
Gynecomastia	7	8.23%
Fat necrosis	3	3.52%
Benign proliferative disease	9	10.58%
Granulomatous mastitis	2	2.35%

Table 3: distribution of malignant breast lesion in cytology

Malignant lesions of breast	Number of cases (N=15)	Percentage %
Atypical changes	3	20%
Ductal carcinoma	9	60
Invasive papillary carcinoma	1	6.66%
Invasive lobular carcinoma	1	6.66%
Lymphoma	1	6.66%

Table 4: neoplastic lesions of breast on histopathology

Neoplastic lesion of breast lesion	Number of cases N=4	Percentage
Breast lymphoma (NHL)	1	25%
Carcinoma of mixed type (invasive NST & Lobular carcinoma)	1	25%
IDC	2	50%

Table 5: Histo-cytological correlation of lesions of breast

Lesions of breast on cytology	Lesions of breast on hpe	Correlated / not correlated
Malignancy	Lymphoma (nhl)	Yes
Fibroadenoma	Fibroadenoma	Yes
Breast abscess	Granulomatous mastitis	No
Fibroadenoma	Fibroadenoma	Yes
Granulomatous inflammation	Graulomatous mastitis	Yes
Fibrocystic disease	Fibrocystic disease with forid ductal hyperplasia	Yes
Benign cystic disease	Fibroadenoma	No
Fibrocystic disease	Carcinoma of mixed type	No
IDC	Idc	Yes
Fibroadenoma	Fibroadenoma with fibrocystic changes	Partially correlated
Benign proliferative disease	Benign phyllodes tumor	No
Benign proloferative disease	Fibroadenosis	Yes
Fibroadenoma	Fibroadenoma	Yes
Granulomatous mastitis	Granulomatous mastitis	Yes
Fibrocystic disease	Benign breast disease	Yes
Benign proliferative disease	Fibroadenoma with fibroadenosis	Yes
Benign proliferative disease	Fibroadenoma	No
Fibroadenoma	Fibroadenoma	Yes
Fibroadenoma	Fibroadenoma	Yes
Fibroadenoma	Fibroadenoma	Yes
Subacute mastitis	Chronic mastitis	Yes
Proliferative breast disease	Idc	No
Total=22		22

Table 6: result of statistical data of cyto-histologically correlated cases after analysis in the present study

True positive	3
True negative	18
False positive	0
False negative	1
Sensitivity	75%
Specificity	100%
Positive predictive value	100%
Negative predictive value	94.73%
Accuracy	95.45%

Table 7: showing detail of male breast lesions

Age	Presentation	Lesions
18	Left sided breast lump	Gynaecomastia
22	Right sided breast lump	Gynaecomastia
35	Right sided breast lump	Gynaecomastia
10	Left sided breast lump, mobile	Gynaecomastia
34	Right sided breast lump with tenderness	Gynaecomastia
82	Left sided breast lump with pain	Gynaecomastia
87	Left sided breast lump	Gynaecomastia

DISCUSSION

Breast lumps are one of the commonest findings in women attending surgical clinics, presence of a lumps invokes a sense of fear and insecurity among these women and all the lumps are believed to be malignant, since breast malignancy is very much amenable to curative treatment when detected early, so it becomes essential that malignancy is detected at earlier stages.

Breast lesions are increasing day by day, they are mostly seen in young age in between 21-40 years. In our series maximum cases (32%) were seen between 21-30 years which is comparable to Divyashree et al which also noted maximum number of cases (31.33%) in 3rd decade(21-30) years.^[13] Jadhav et al 2017 reported that 37.2% cases were seen in 3rd decade,^[14] contradictory to Rathi et al 2022 found (37.09%) cases in between 31-40 years.^[14] In all the series incidence of cancer breast declines after 50 years (10.8%-18.24%) which is similar to our study. Cancer breast is a rare in male even benign breast diseases are also uncommon in males. As compared to other series (Ashraf et al 2015,^[15] Aslam et al 2013,^[16] Divyashree et al,^[14] 2018), in our series incidence of breast lesions in male patient was high (7% vs 3.9%, 0.82% and 4.8%)

Unilateral involvement of breast was common in both benign and malignant lesions. In our series involvement of left breast was more common (46% vs 41%), than right breast which is more or less similar to study of yerakly et al,^[17] 2022 and Rathi et al 2022 Contradictory to it, right breast was more involved in other series Syed. Sarfraz et al,^[18] series 2021 and Raja Nazam et al 2021,^[19] Kaushik et al 2022.^[20] Bilateral involvement was more common in present study (13%) which is very much higher than in other series where it varies from (1.17%-6%).

In present study 48% of the patient presented between 4-6 months, 33% of the patients came to doctor in less than 3 months and 18% cases presented between 7-9 months only one patient presented after 9 months.

This study was in contrast with Singh et al,^[21] (2016) in which (36.84%) patient presented in less than 6 months duration, (42.11%) of patient presented in between 6 months -1 year and (21.05%) patients presented after 1 year.

Lump in breast was present in all the cases of breast disease similar to us Embaye et al 2020,^[22] found lump in breast in 98.56% cases contrary to it Sahu et al,^[23] reported it in only 57% cases. In other series

also it was the predominant feature (Vanisha et al 74.8%,^[24] Jandid et al 79.25%).^[25]

Pain was uncommon feature was found in 16% cases in our series but some series Mahalaxmi et al,^[26] 2020 (50%) and Sahu et al,^[23] 2021(77%) reported it at in very higher frequency reason for it is not clear.

Most of the lesions of breast were present in upper outer quadrant present in various series (Singh et al 2016,^[21] Kazi Farzana et al 2018,^[27] Agarwal et al 2021),^[28] but some study (Haq et al 2021)^[29] reported 88.4% in upper outer quadrant, In our cases 28% lesions were in upper inner quadrant which is more or less similar to other studies. (Singh et al, Kazi et al and Agrawal et al) but Haq et al found it in only 6.7% cases . Left inner quadrant was involved in 17% of our cases but it was seen in only 1.8-9% in other series (Haq et al, Singh et al, Farzana et al, Agrawal et al).

In the present study, majority of the cases belonged to benign (84%) of the cases. Frequency of benign lesion range from (36%) to (87%). Our study is concordance with other studies, (Rathi et al 2015, Yadav et al 2020)

Malignant breast lesions were seen in only 16% cases which is more or less similar to Rathi et al and Srivastva et al.^[30] Some studies (Fakede et al 2022) reported malignancy in 49% cases.^[31]

Non neoplastic lesions in the breast were more common than neoplastic. Among it fibroadenoma was the most common lesion found in (53.53%) cases, in other series (Savita et al 2015 and Das et al 2018) incidence of fibroadenoma was much more (77% and 65.2%).

Benign proliferative disease was found in (10.7%) cases in our series but in other series frequency was low i.e (2.33% to 5.40%).

Fibrocystic disease (16.16%) was more or less similar to Das et al (15.21%). Gynecomastia was found in 8.3% of our cases where as other series reported (Das et al 2018, Khanam et al 2018, Savita et al 2015) it in very low frequency varying from 2.1% to 4.05%.

Neoplastic including atypical lesions was found in only 15 cases on FNAC. Infiltrating duct carcinoma was found to be more common in all the series. Our lesions of IDC (60%) were comparable to (Quadri et al 2022)33 while in other series it was much more common. Invasive lobular carcinoma, lymphoma were uncommon. It was not noted in series of (Savita et al 2015, Ankita et al 2018, Quadri et al 2022).

Invasive papillary carcinoma was seen in our series is low percentage i.e (6.6%) whereas Quadri et al found it in 30.3% cases, other series did not describe it.

Primary non-Hodgkin lymphoma of breast is very rare. It account for only 0.1% to 0.5% of all reported malignant breast tumours and 1.7% to 2.2% of all extra nodal NHL lymphoma of breast are usually of non Hodgkin's type. (Gary Tozbikian 2023)³

Histopathology was done in 22 csaes only. Benign lesions were more common (63.63%) followed by equal findings of inflammatory and malignant lesions. Predominance of benign lesions were recorded by other series, also but in much higher frequency (Aslam et al 2013, Jadev et al 2017, Shree et al 2018 and Shrivastav et al 2019).

Malignancy in histopathology in breast lesions was seen in only 18.18% cases, which is more or less similar to study of shree et al 2018 and shrivastav et al 2019.

Fibroadenoma was the most common lesions in histopathology seen in all series, (Raj kumar et al 2017, Chavan et al 2019, Yadav et al 2020). Second most common lesion in our series was chronic mastitis ie. 16.6% but in other series it was uncommon (1.3-7.28%), fat necrosis was seen in 3 cases of FNAC but in that cases histopathology was not done. Duct papilloma, adenoma, hamartoma were not seen in our series. Out of 3 cases of chronic mastitis, one case was of granulomatous mastitis, which revealed non caseating granuloma with pinkish material, which was positive for amyloid in Congo red. It was seen in 35 year old muslim lady.

IDC breast was the most common malignant lesions (50-90%), in which 1 case was lymphoma and another case was of mixed lobular carcinoma and invasive duct carcinoma. Mucinous carcinoma, metaplastic carcinoma, duct carcinoma in situ, pagets, papillary carcinoma were not found in present series. This might be due to the fact that our number of cases were very small (only 4 cases). In our series also many malignant lesions were detected in FNAC but patient went to advance hospital for treatment hence HPE was not available.

Malignant lymphoma is a neoplasm which originates in lymphatic tissue. Primary non-Hodgkin's lymphoma of the breast is very rare and a distinct entity in the diagnosis of breast malignancies, accounting for only about 0.1 to 0.5% of all reported malignant breast tumors and for 1.7–2.2% of extra nodal NHL. There are various kinds of breast lymphomas, but the most common is the B cell non-Hodgkin's lymphoma.¹⁰²

Study on male breast lesions are scarce, Samantara etal 2017 studied 158 cases of male breast lesions found in 7 years. In male also benign lesions (82.9%) were more predominant as compared to malignant lesions(17.8%). In benign lesions gynecomastia predominated (72.78%), where as in malignant lesions infiltrating duct carcinoma is predominant. They found prevalence of male breast lesions to be 2.5%. The mean age of male malignant patients were 56 years (range 32-82 years). They reported specificity of FNA to 100% but sensitivity of only 87% and diagnostic accuracy of 94.93%.In our cases age of the male patient varied from 10-87 years and

all cases were of Gynaecomastia. All cases were successfully diagnosed by FNAC.

Sensitivity of FNAC in comparison to other studies in present study was 75% whereas in other studies listed in table 23, It was very high and varied from 75% to 93.84%. Positive predictive value of FNAC in comparison to histopathology was 100%, whereas other studies also found same (100%).However specificity in our study was 100% which is more or less similar to our study, Samantara et al and Das et al found specificity of 100%.

CONCLUSION

Study suggest that fibroadenoma is the most common benign lesion of breast seen in early ages(19 year) whereas infiltrating duct carcinoma was the commonest malignant lesion of breast, found to be more common in 41-50 year of age group, most common site for breast lump is left breast (UOQ).Fine needle aspiration cytology is very important preliminary diagnostic tool in palpable breast lump and result show high degree of correlation with final HPE report, FNAC is less time consuming, safe, useful and highly accurate technique for breast masses with sensitivity of 75% and can segregates benign and malignant lesions with accuracy.

Hence FNAC can play a major decisive diagnostic role and minimizing the requirement of biopsy. Histopathology is superior and confirmatory test in breast biopsy. Immunohistochemistry in malignant lesions is essential for classification for determining treatment and for knowing prognosis of cancer breast.

REFERENCES

1. Aslam HM, SaleemS, Shaikh HA, Shahid N, Mughal A, Umah R.Clinico- pathological profile of patients with breast diseases. *DiagnPathol.* 2013; 8:77
2. Mansoor I: Profile of female breast lesions in Saudi Arabia. *JPMA* 2001,51(7):243–246.3.
3. Khanna R, Khanna S, Chaturvedi S, Arya NC. Spectrum of breast disease in young females: A retrospective study of 1315 patients. *Indian J Pathol Microbiol* 1998;41(4):397-401
4. Khemka A, Chakravarthi N, Shah S, Patel V. Palpable breast lumps: fine needle aspiration cytology versus histopathology, a correlation of diagnostic accuracy. *Internet J surgery.* 2009;18:1.
5. Hutchinson WB, Thomas DB, Hamlin WB, Roth GJ, Peterson AV, Williams B. Risk of breast cancer in women with benign breast disease. *J Nat Canc Instit.* 1980;65(1):13-20.
6. Mansel RE. Benign breast disease. *Practitioner.* 1982;232:830-37.
7. Sainsbury RC. Bailey and Love's Short Practice of Surgery .25th. London: Edward Arnold Ltd; 2008. Breast IN: Norman WS, Bulstrode CJK, P, Ronan O'Connell editors; pp.827-35.
8. Love SM, Gelman RS, Silen W. Fibrocystic diseases of the breast – a non-disease? *N Eng J Med.*1982;309:1010-4
9. Anyanwu, S. N. (2008). Temporal trends in breast cancer presentation in the third world. *Journal of Experimental & Clinical Cancer Research*, 27(1), 17.
10. Guray, M., & Sahin, A. A. (2006). Benign breast diseases: classification, diagnosis, and management. *The oncologist*, 11(5), 435-449.

11. Memon shima sultan, valiram P, Saleh Memon Clinicopathological profile of breast lesions at a tertiary care centre in Karachi, Pakistan, *Pak J Surg* 2020; 36(1):25-28
12. Yadav Deepti, Meel Mukta, Hemrajani Deepika, Mittal Aarti, Mathur Kusum An audit and clinicopathological study of fibroepithelial lesions of the breast at a tertiary care centre and comparison with WHO grading, *Internal Surgery journal* 2020,7(7),2241-2246.
13. Divyasree N, Atla B, Kumar SS, Lavanya L, Reddy KS. Clinicopathological study of breast lesions over a period of one year in a tertiary care center. *Int J Res Med Sci* 2018;6:3397-402
14. Jadhav Dnyaneshwar S. et. al. / A Histopathological Study of Neoplastic and Non-Neoplastic Breast Lesions, *Indian Journal of Pathology: Research and Practice / Volume 6 Number 2 / April - June 2017 (Part 2);388-392.*
15. Ashraf a., shaikh a.s., saba k.,bukhari m.h.and kamal f. Clinicopathological study of breast carcinoma. *biomedica vol.31,issue 4 oct-dec.2015;328-331.*
16. Aslam, H. M., Saleem, S., Shaikh, H.A. et al. Clinicopathological profile of patients with breast diseases. *Diagn Pathol* 8,77(2013). <https://doi.org/10.1186/1746-1596-8-77>.
17. Yerakly F, Tadele AK. Histopathologic Patterns of Breast Lesions in Hawassa University Comprehensive Specialized Hospital, Sidama Region, Ethiopia: A Six-Year Retrospective Study (September 2015 G.C to August 2020 G.C.). *Clin Oncol.* 2022; 7: 1895. ISSN: 2474-1663
18. Ali S S, Pehlajani N, Rai E, Histopathological spectrum of breast lesions *MedPulse International Journal of Pathology*, Print ISSN: 2550-7605, Volume 20, Issue 1, October 2021 pp 27-30
19. Haq RN, Shabbir RK, Saad M. Clinicopathological Variants of Breast Cancer in A Tertiary Care Hospital in Pakistan. *APMC* 2021;15(1):28-31. DOI: 10.29054/APMC/2021.828
20. Saha K, Raychaudhuri G, Chattopadhyay BK. Clinicopathological study of breast carcinoma: A prospective two-year study in a tertiary care hospital. *Clin Cancer Investig J* 2013;2:34-40.
21. Singh SK, Pankaj D, Kumar R, Mustafa R. A clinicopathological study of malignant breast lump in a tertiary care hospital in Kosi region of Bihar. *Int Surg J* 2016;3:32-6.
22. Embaye KS, Raja SM, Gebreyesus MH, Ghebrehiwet MA. Distribution of breast lesions diagnosed by cytology examination in symptomatic patients at Eritrean National Health Laboratory, Asmara, Eritrea: a retrospective study. *BMC Womens Health.* 2020 Nov 10;20(1):250. doi: 10.1186/s12905-020-01116-0. PMID: 33172446; PMCID: PMC7654611
23. Sahoo D K, Nandi M M, Basu srijan, Chatterjee S, Das A K, Clinic-Pathological study of carcinoma breast i. *Asian Journal of Medical Sciences | Sep 2021 | Vol 12 | Issue 9.* 75-79
24. Vanisha Dhaka1, Vaibhav P. Mane2,* , Vishrabdha R. Pawar3, D.G. Mote4, Sushant V. Mohite, Clinicopathological study of mastectomy, *Indian Journal of Pathology and Oncology*, July-September 2016;3(3):446-449
25. Angid P, Jangid MK, Pachori G. A histopathological study of malignant lesions of the female breast in a tertiary care centre. *J. Evolution Med. Dent. Sci.* 2020;9(24):1795-1799, DOI: 10.14260/jemds/2020/392
26. Mahalakshmi.P, B.Krishnaswamy, KR. Gopalakrishnan, M. Dhanalakshmi, E . Shyamala et al, A Clinicopathological Evaluation of Breast Carcinoma, *JMSCR nov 22 ;Vol||08||Issue||11||Page 44-48.*
27. Khanama F K, Akterb N, Tabashumb T et al, Study of Various Breast Lesions by FNAC, *J Curr Surg.* 2018;8(3-4):27-31
28. Agrawal N, Kothari K, Tummidi S, Sood P, Agnihotri M, Shah V. Fine-Needle Aspiration Biopsy Cytopathology of Breast Lesions Using the International Academy of Cytology Yokohama System and Rapid On-Site Evaluation: A Single-Institute Experience. *Acta Cytol.* 2021;65(6):463-477.
29. Haq RN, Shabbir RK, Saad M. Clinicopathological Variants of Breast Cancer in A Tertiary Care Hospital in Pakistan. *APMC* 2021;15(1):28-31.
30. Srivastava N.K. Clinico-pathological study of 200 cases of Breast lesions in a tertiary care centre of Rohtas, Bihar, India. *Trop J Path Micro* 2019;5(6):338-342.
31. Yerakly F, Tadele AK. Histopathologic Patterns of Breast Lesions in Hawassa University Comprehensive Specialized Hospital, Sidama Region, Ethiopia: A Six-Year Retrospective Study (September 2015 G.C to August 2020 G.C.). *Clin Oncol.* 2022; 7: 1895. ISSN: 2474-1663
32. Qadri S, Khan SP, Farooq S, Bhat AR. Cytomorphological pattern of breast lesions diagnosed on fine-needle aspiration cytology in a district hospital in Kashmir valley. *Int J Adv Med* 2022;9:814-7.